

First experiences with hysterosalpingo-foam sonography (HyFoSy) for office tubal patency testing

Mark Hans Emanuel^{1,*}, Michelle van Vliet¹, Maaïke Weber¹, and Niek Exalto²

¹Department of Obstetrics and Gynaecology, Spaarne Ziekenhuis Heemstede/Hoofddorp, PO Box 770, 2130 AT Hoofddorp, The Netherlands ²Department of Obstetrics and Gynaecology, Division of Obstetrics and Prenatal Medicine Erasmus MC, University Medical Centre, Rotterdam, The Netherlands

*Correspondence address. Tel: +31-23-8908900; E-mail: m@emanuel.nl

Submitted on July 2, 2011; resubmitted on October 2, 2011; accepted on October 6, 2011

BACKGROUND: This study was conducted to describe the first experiences with hysterosalpingo-foam sonography (HyFoSy) as a first step routine office procedure for tubal patency testing.

METHODS: A prospective observational cohort study was started in a university affiliated teaching hospital. In 2010, 73 patients with subfertility and a low risk of tubal pathology were examined. A non-toxic foam containing hydroxymethylcellulose and glycerol was applied through a cervical applicator for contrast sonography (HyFoSy). Tubal patency was determined by transvaginal ultrasonographic demonstration of echogenic dispersion of foam in the Fallopian tube and/or the peritoneal cavity. Only in case patency could not be demonstrated, a hysterosalpingography (HSG) was performed as a control.

RESULTS: In 67 out of 73 (92%) patients, a successful procedure was performed. In 57 out of 73 (78%) cases, there was no further need for a HSG. In five patients (5/73; 7%) tubal occlusion was confirmed by HSG and in five patients (5/73; 7%) there was discordance between HyFoSy and HSG. Of 73 patients, 14 (19%) conceived within a median of 3 months after the procedure.

CONCLUSIONS: HyFoSy is a successful procedure to demonstrate tubal patency as a first step office procedure.

Key words: Fallopian tube patency tests / infertility / hysterosalpingography / ultrasound

Introduction

Assessment of Fallopian tube patency is an important part of routine infertility work-up as tubal obstruction is estimated to play a role in 12–33% of infertile couples (Collins *et al.*, 1995; Snick *et al.*, 1997). Several tests are available for this purpose, including hysterosalpingography (HSG), laparoscopy with a dye test, selective salpingography and hysterosalpingo-contrast sonography (HyCoSy). The latter allows assessment of the outline of the uterine cavity and patency of the Fallopian tubes, and the investigation can be performed with standard transvaginal ultrasonography equipment as an office procedure. The accuracy of HyCoSy has been found to be comparable with that of HSG (Reis *et al.*, 1998; Dijkman *et al.*, 2000).

A commonly used echogenic medium for HyCoSy was Echovist[®] (Bayer Schering Pharma AG, Berlin, Germany), a suspension of slowly soluble galactose microparticles in an aqueous solution

(<http://www.rxmed.com>). No allergic-type reactions for Echovist[®] have been reported so far, but galactose allergy is a well known contra-indication.

Recently Echovist[®] has become no longer available for gynaecological use. Unfortunately, there are no other ultrasound contrast media labelled and registered for gynaecology. It has been suggested by others to use air with saline as a cheap and easy-to-use alternative (Spalding *et al.*, 1997). However, as air bubbles disappear directly after mixing air and saline by shaking, it is only possible to inject air and saline intermittently into the uterine cavity by tilting a syringe filled with air and saline in order to alternate which is injected. Adverse reactions other than pain (vasovagal reactions, nausea, vomiting, hyperventilation and sweating) related to the saline-air solution have been recorded in 5% of cases (Savelli *et al.*, 2009).

In 2007, a non(embryo-) toxic gel (ExEm-gel[®]; GynaecologIQ, Delft, The Netherlands), containing hydroxyethylcellulose and

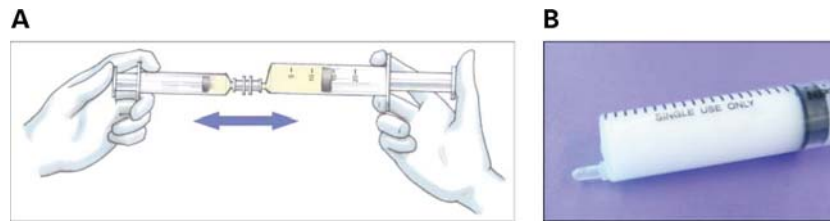


Figure 1 (A) The foam is created by rigorously mixing 10 ml ExEm-gel[®] with 10 ml of purified water in a 20 ml syringe. (B) Syringe filled with foam.

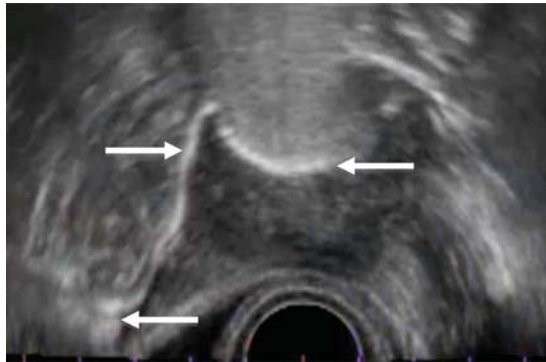

Figure 2 Uterine cavity, patent right tube and spillage in the abdominal cavity (the left tube is not visible in this plane).

glycerol, was introduced and registered for the dilatation of the uterine cavity during sonography, being an intrauterine medium for sonohysterography, as an alternative to saline (Exalto et al., 2007). When this gel is diluted and pushed rigorously through small openings in syringes or tubes, turbulence will cause a local pressure decrease resulting in air being dissolved in the solution, thus yielding foam that is stable for several minutes.

The aim of this study is to describe the first experiences with this foam as a first step routine office procedure for tubal patency testing.

Materials and Methods

In our centre in 2010, a total of 73 patients with subfertility were examined with HyFoSy to demonstrate tubal patency. The mean age of the patients was 34 years (range 26–44). Their mean BMI was 24.5 (range 18.4–41.1). The mean duration of subfertility was 2.2 years (range 0.5–7); 23 patients were nulligravidae, 30 patients were nulliparous and 43 patients were multiparous. The median number of previous pregnancies was two (range 0–7) and the median parity was one (range 0–3). All patients were at low risk for tubal disease. Chlamydia antibody testing (CAT) was negative in all patients and no patients had a history for tubal surgery.

ExEm-gel[®] is rather viscous for passing into the Fallopian tubes, however after dilution with purified water, already being one of the basic compounds of ExEm-gel[®], it allows passing through patent Fallopian tubes. Foam was created by rigorously mixing 10 ml ExEm-gel[®] (containing 88.25% purified water) with 10 ml of purified water (to give a mixture containing 94.10% water) in a 20 ml syringe (Fig. 1A and B). This recipe turned out to be excellent for creating foam that was sufficiently stable to show echogenicity for at least 5 min and

for providing sufficient fluid to pass through patent tubes. Viscosity measurements revealed a lower viscosity for ExEm foam (270 cPs) when compared with Echovist[®] (400 cPs). The ability of ExEm foam to pass through the Fallopian tube is therefore expected to be at least comparable with Echovist[®].

After inspection of the uterine cervix with the use of a side-opened speculum, a cervical balloon-less applicator (designed for Gel Instillation Sonography by GynaecologiQ BV, Delft, The Netherlands), connected to the syringe with foam, was placed. In a minority of patients, with a sharp ante- or retroverted uterus or a pin-point ostium externum, the use of a tenaculum was necessary. After removal of the speculum, the ultrasound transducer was introduced into the vagina and the uterus was visualized in the longitudinal plane. The foam was then introduced into the uterine cavity by pushing the plunger of the syringe with light pressure by an assistant. After identifying the foam in the uterine cavity in the longitudinal plane, the transducer was rotated to the transverse plane to visualize the distension of the Fallopian tubes on both sides. Visualization of the dispersion of the foam in the peritoneal cavity was easier after localizing the ovaries.

Only in cases where uterine cavity distension or Fallopian tube distension on one or both sides could not be visualized, a hysterosalpingogram (HSG) was performed.

Results

In 67 out of 73 (92%) patients, the procedure was successful in terms of an adequate filling of the uterine cavity. In 6 out of 73 (8%) patients, filling of the uterine cavity was inadequate due to cervical blockage in 5 patients and leakage in 1 patient. HSG revealed that in three patients, the cervix was indeed blocked and in another three patients, the results were normal. In 55 out of the 73 (75%) patients, passage of the contrast through both normal appearing tubes was clearly visible separately with or without filling of the Douglas pouch with the foam (Fig. 2). In two patients with only one tube present, this tube was patent ultrasonographically. In total, in 57 out of 73 (78%) patients no further examination was necessary (Fig. 3). In another five (5/73; 7%) patients, only one tube was visible. HSG revealed that in three of them indeed only one tube was patent, including one case with a sactosalpinx and in two (2/73; 3%) cases both tubes were patent instead of one as suggested by HyFoSy. In five (5/73; 7%) other patients both tubes were not visible with ultrasound; HSG revealed that two of them had blocked tubes and three (3/73; 4%) of them had patent tubes. So in 5 out of 10 patients (5/73; 7%) with no or just one patent tube according to HyFoSy, there were discordant findings between HyFoSy and HSG. In the other five patients the findings with HyFoSy were confirmed by HSG.

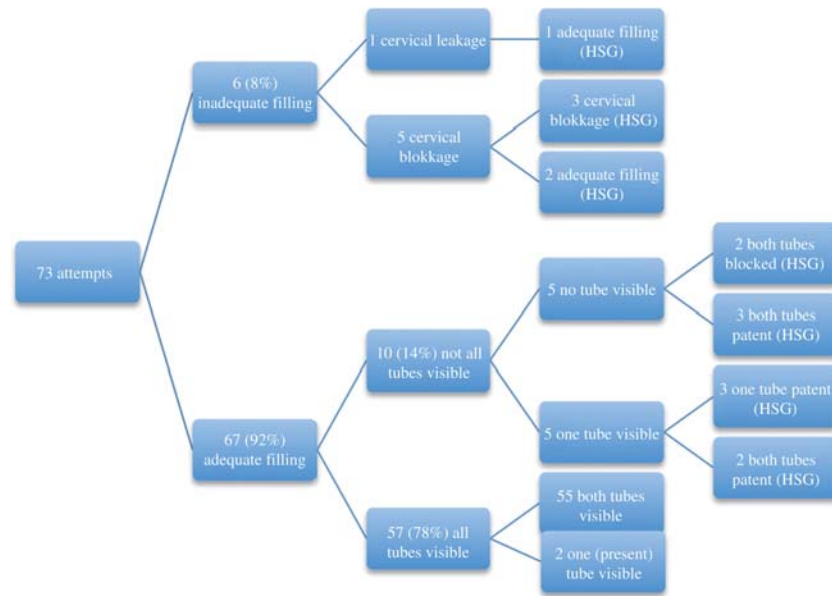


Figure 3 Flow-chart of all patients examined (HSG, hysterosalpingogram).

Five patients (5/73; 7%) had vasovagal discomfort during or after the procedure that resolved spontaneously in time. All procedures were uneventfully and no serious side-effects were observed.

Furthermore, in 14 out of 73 (19%) patients, a spontaneous pregnancy occurred following the procedure. The median time between the HyFoSy procedure and the detection of the pregnancy was 3 months (range 2–12).

Discussion

This is the first study reporting on experiences with infusion of foam as a first step office procedure for testing tubal patency with the use of ultrasound. For evaluation of the uterine cavity, we prefer gel instillation sonohysterography with undiluted ExEm-gel[®], as the echogenicity of the foam can mask intracavitary abnormalities.

This gel and its compounds have been tested extensively and safely used in medicine. Its compounds are also described in artificial tears and adhesion barriers (Elam and Elam, 1993; Falk *et al.*, 1998; O'Brien *et al.*, 2003; Berger *et al.*, 2005; Nilforoushan *et al.*, 2005). Toxicity was extensively tested (on embryos, in blood and in the peritoneal cavity) and described in the registration file. To date, more than 30 000 gel instillation procedures with ExEm-gel[®] have been performed without any serious side effects (personal communication with the manufacturer). As the ingredients of this foam are equal to ExEm-gel[®], we expect that allergy and complications will be equally rare. No precautions are needed with regard to pregnancy in the HyFoSy cycle.

It has been concluded already in the literature recently that CAT-negative patients should have a HyCoSy that carries a similar cost and has at least the same accuracy as HSG (Lim *et al.*, 2011). In addition to testing for tubal patency, it can be expected that with the increasing use of hysteroscopic sterilization techniques, (contrast) sonography will also play a more important role as a reference test

for demonstrating adequate positioning of intratubal devices and/or tubal blocking.

A limitation of the study is that it is not a randomized controlled study comparing HyFoSy with HSG or laparoscopy with dye. Our experiences and our number of successful procedures with HyFoSy are comparable with different HyCoSy studies (Papaioannou *et al.*, 2004; Savelli *et al.*, 2009). We have chosen to perform a HSG only in cases where patency could not be demonstrated in one or more tubes. It should also be mentioned that there are no dedicated ultrasound contrast media that are labelled and registered for gynaecology other than Echovist[®]. As the viscosity of ExEm gelfoam is even lower than HyCoSy with Echovist[®], we could expect that HyFoSy would perform at least as well as HyCoSy in terms of demonstrating tubal patency.

We have demonstrated, using HyFoSy for tubal patency testing, that a HSG can be avoided in about 78% of infertility cases. HyFoSy is a clean and safe, non(embryo-) toxic and a less expensive alternative to HyCoSy, that can be performed by a single operator in the office or ambulatory setting as a first step test of tubal patency.

Authors' roles

M.H.E. is the inventor of the technique and performed a number of procedures. He is the principal author. M.v.V. performed a number of procedures and analysed the results. M.W. co-analysed the results. N.E. is the co-inventor of the technique and performed a number of the procedures. He is the main co-author.

Conflict of interest

M.H.E. and N.E. hold stock in GynaecologiQ BV, the makers of ExEm-gel[®] and receive royalties from GynaecologiQ BV.

References

- Berger C, Sakowitz OW, Kiening KL, Schwab S. Neurochemical monitoring of glycerol therapy in patients with ischemic brain edema. *Stroke* 2005;**36**:e4–e6.
- Collins JA, Burrows EA, Wilan AR. The prognosis for life birth among untreated infertile couples. *Fertil Steril* 1995;**64**:22–28.
- Dijkman AB, Mol BW, van der Veen F, Bossuyt PM, Hogerzeil HV. Can hysterosalpingocontrast-sonography replace hysterosalpinography in the assessment of tubal subfertility?. *Eur J Radiol* 2000;**35**:44–48.
- Elam JH, Elam M. Surface modification of intravenous catheters to reduce local tissue reactions. *Biomaterials* 1993;**14**:861–864.
- Exalto N, Stappers C, van Raamsdonk LAM, Emanuel MH. Gel instillation sonohysterography: first experience with a new technique. *Fertil Steril* 2007;**87**:152–155.
- Falk K, Holmdahl L, Halvarsson M, Larsson K, Lindman B, Bengmark S. Polymers that reduce intraperitoneal adhesion formation. *Br J Surg* 1998;**85**:1152–1156.
- Lim CP, Hasafa Z, Bhattacharya S, Maheshwari A. Should a hysterosalpingogram be a first-line investigation to diagnose female tubal subfertility in the modern subfertility workup?. *Hum Reprod* 2011;**26**:967–971.
- Nilforoushan MR, Latkany RA, Speaker MG. Effect of artificial tears on visual acuity. *Am J Ophthalmol* 2005;**140**:830–835.
- O'Brien JM, Houseman BA, Allen AA, Barton JR. Methylcellulose gel is superior contrast agent for ultrasonographic examination of the cervix in obstetric patients. *Ultrasound Obstet Gynecol* 2003;**21**:149–151.
- Papaoannou S, Bourdrez P, Varma R, Afnan M, Mol BW, Coomarasamy A. Tubal evaluation in the investigation of subfertility: a structured comparison of tests. *BJOG* 2004;**111**:1313–1321.
- Reis MM, Soares SR, Cancado ML, Camargos AF. Hysterosalpingocontrast sonography (HyCoSy) with SH U 454 (Echovist) for the assessment of tubal patency. *Hum Reprod* 1998;**13**:3049–3052.
- Savelli L, Pollastri P, Guerrini M, Villa G, Manuzzi L, Mabrouk M, Rossi S, Seracchioli R. Tolerability, side effects, and complications of hysterosalpingocontrast sonography (HyCoSy). *Fertil Steril* 2009;**92**:1481–1486.
- Snick HK, Snick TS, Evers JL, Collins JA. The spontaneous pregnancy prognosis in untreated subfertile couples: the Walcheren primary care study. *Hum Reprod* 1997;**12**:1582–1588.
- Spalding H, Martikainen H, Tekay A, Jouppila P. A randomised study comparing air to Echovist as a contrast medium in the assessment of tubal patency in infertile women using transvaginal salpingosonography. *Hum Reprod* 1997;**12**:2461–2464.